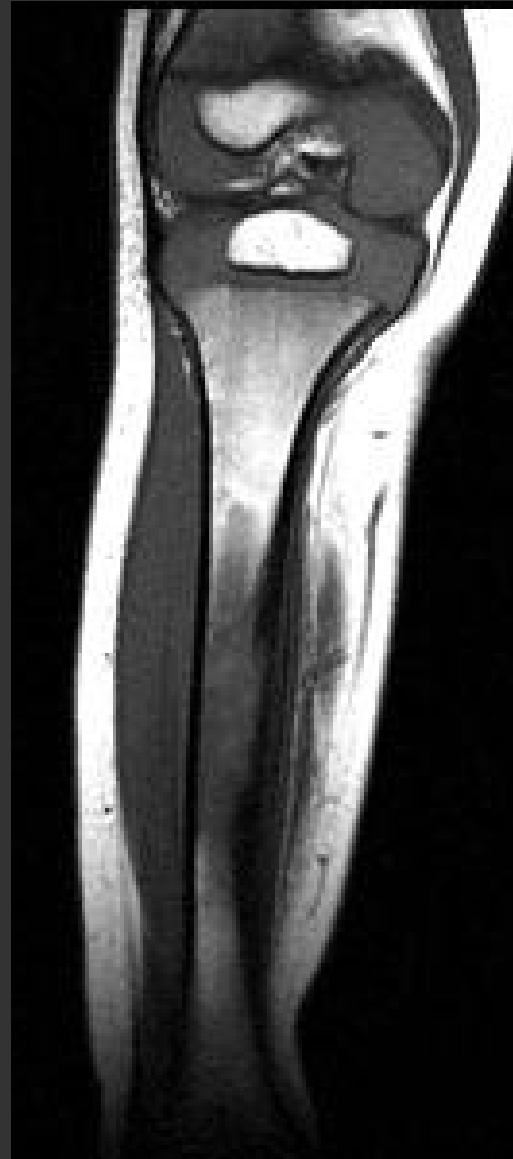
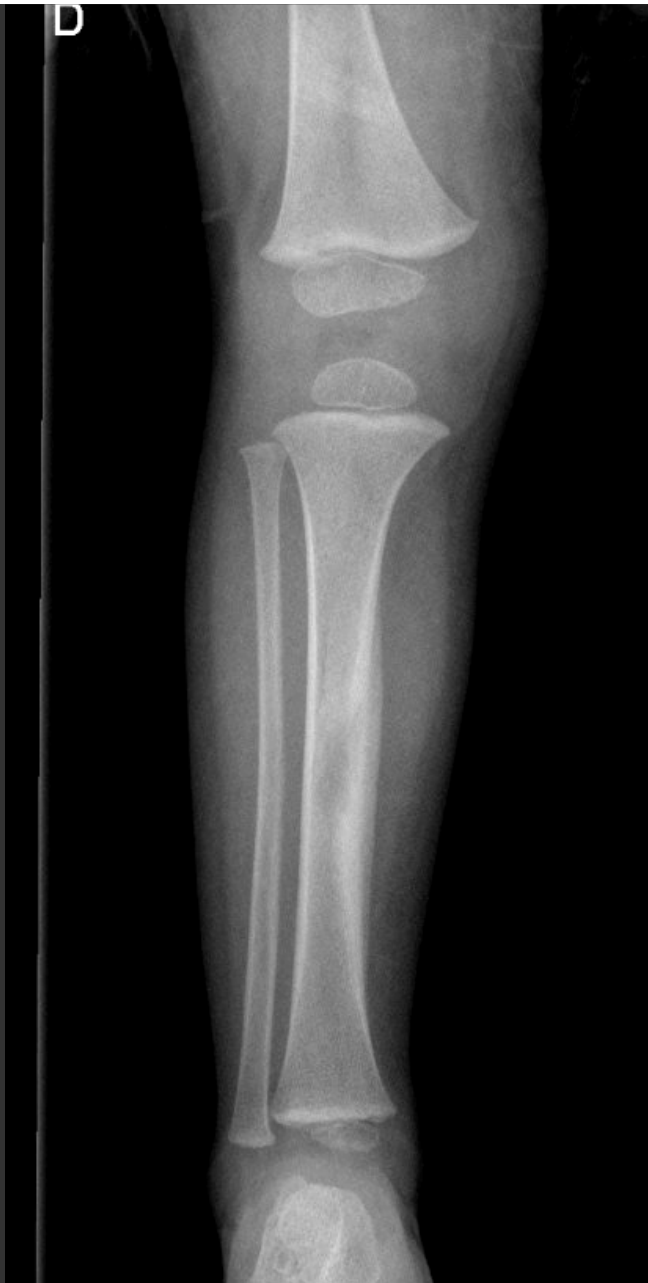
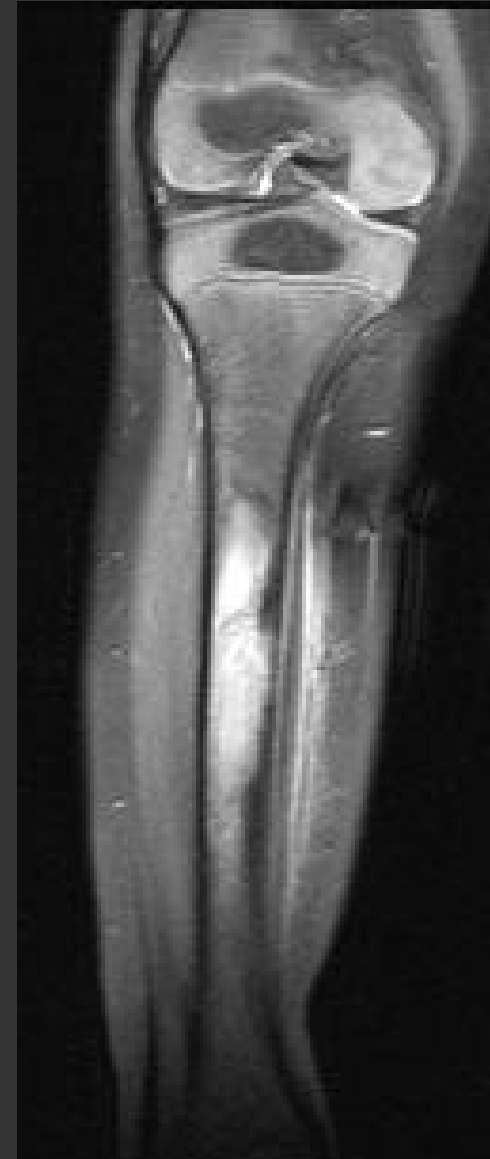# Case 7

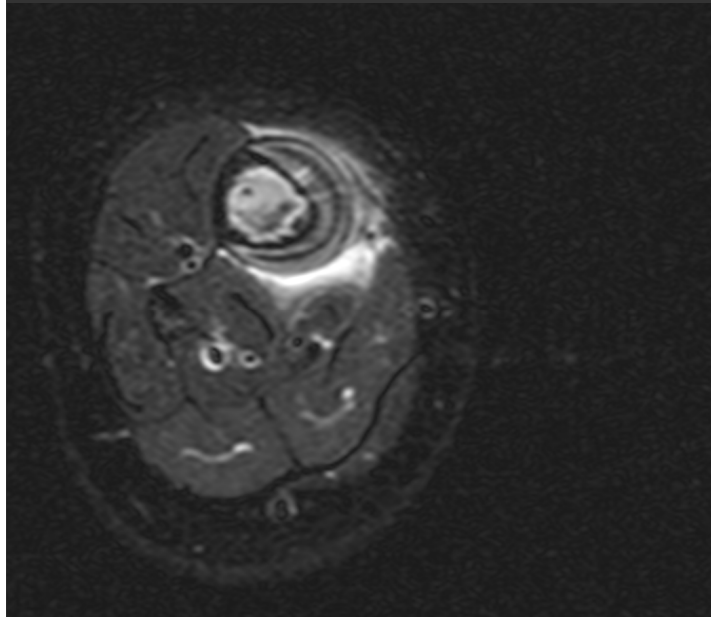
- Boy, 18 months old.
- Pain and difficulty weight-bearing.



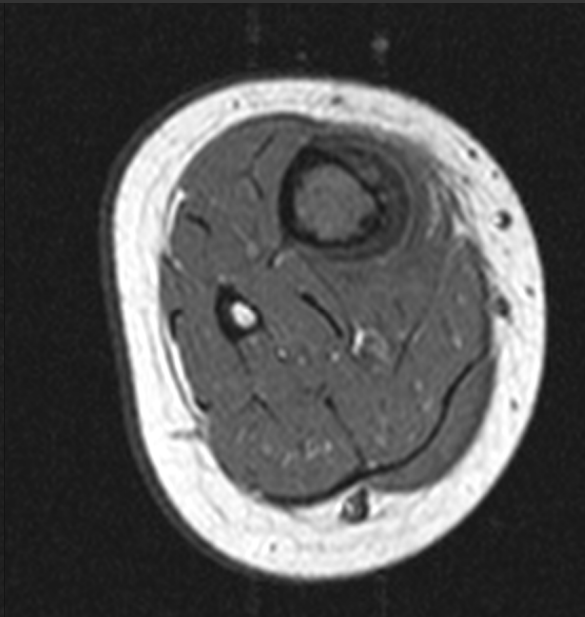
**Coronal T1 WI**



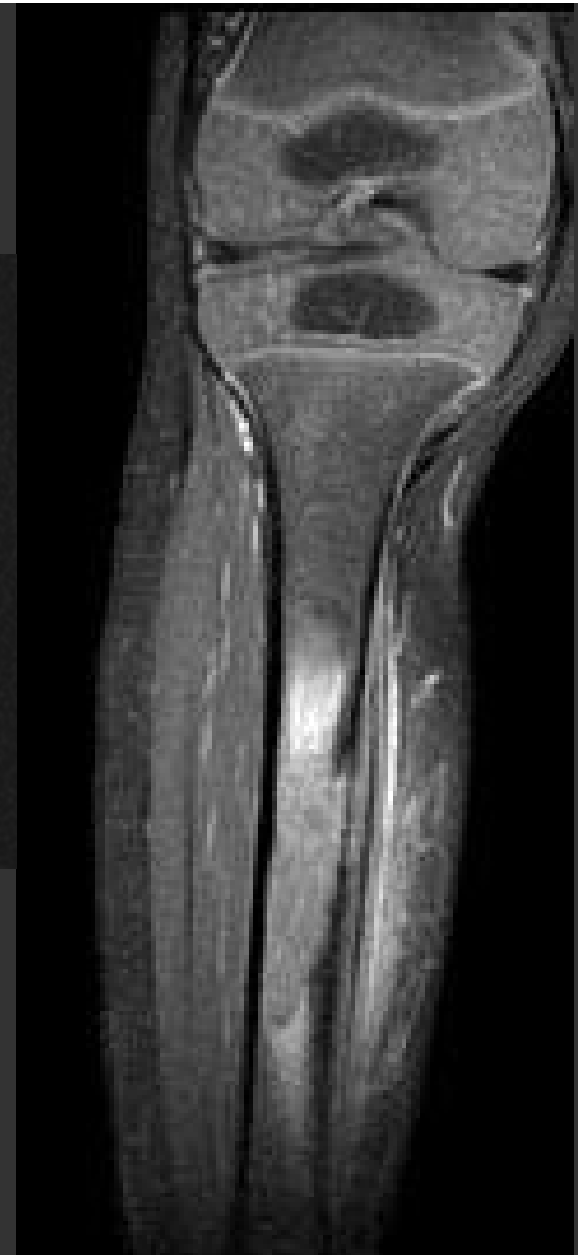**Coronal STIR**  
Case 7



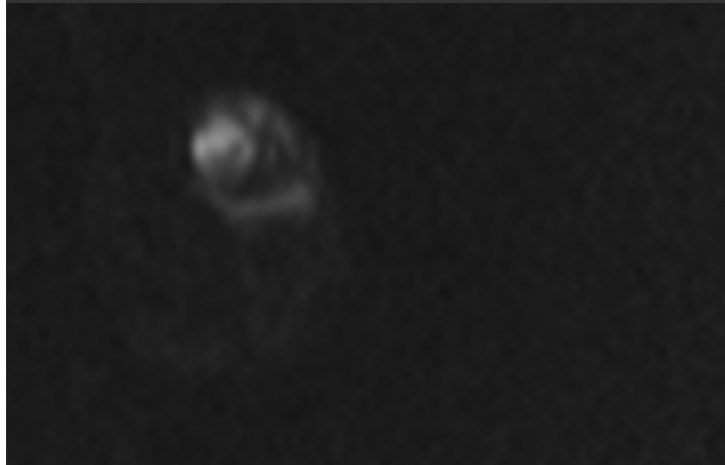**Axial T2 FS WI**



**Axial T1 WI**



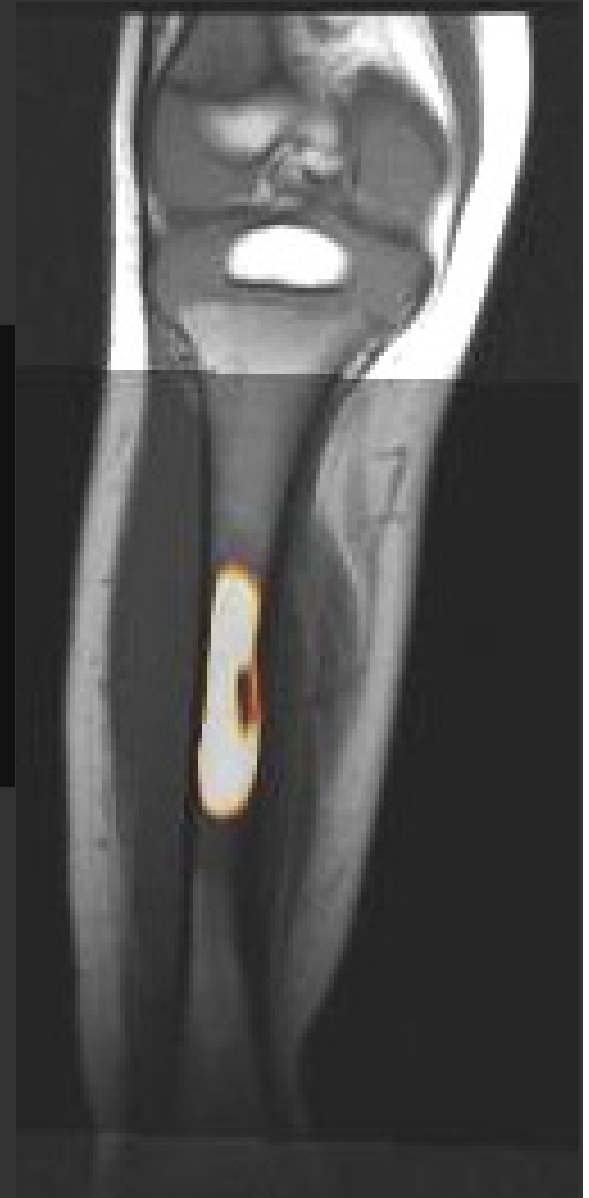
**Coronal T1FS WI Gad**



DWI



ADC



DWI-T1WI FUSION