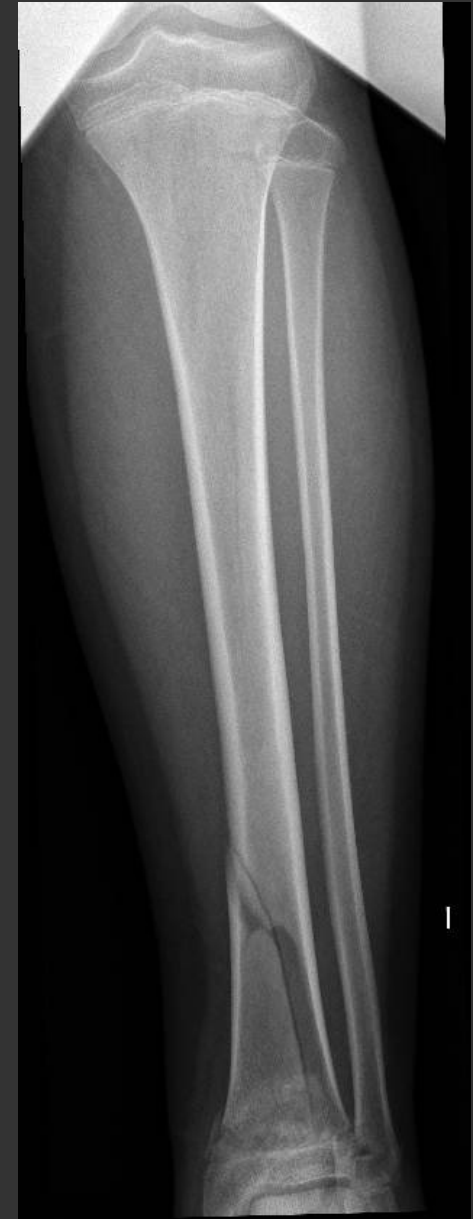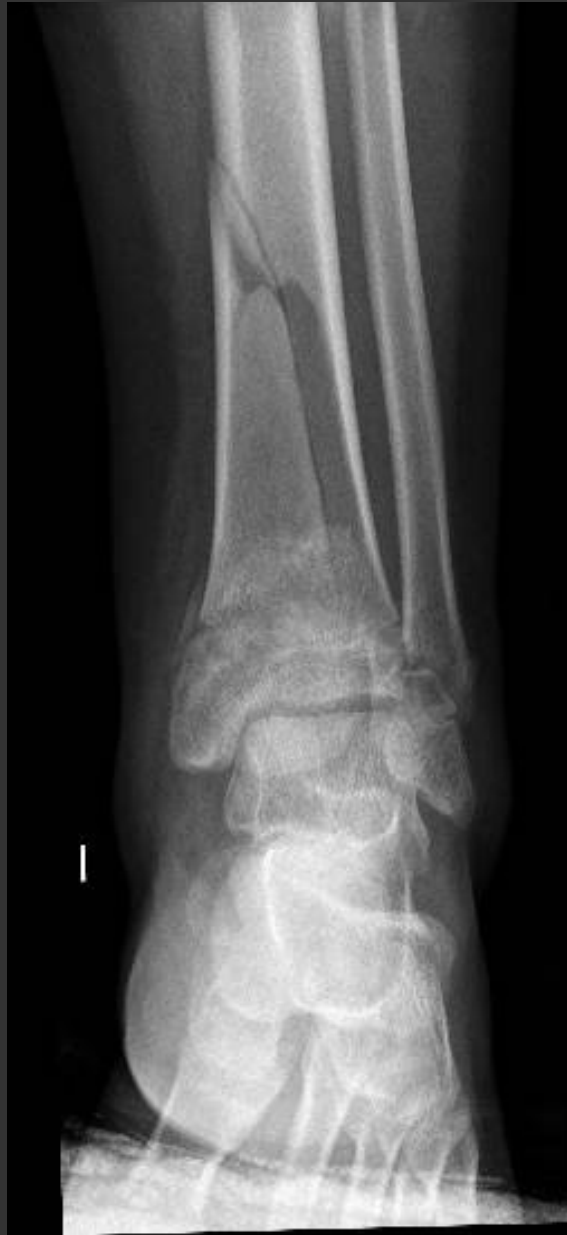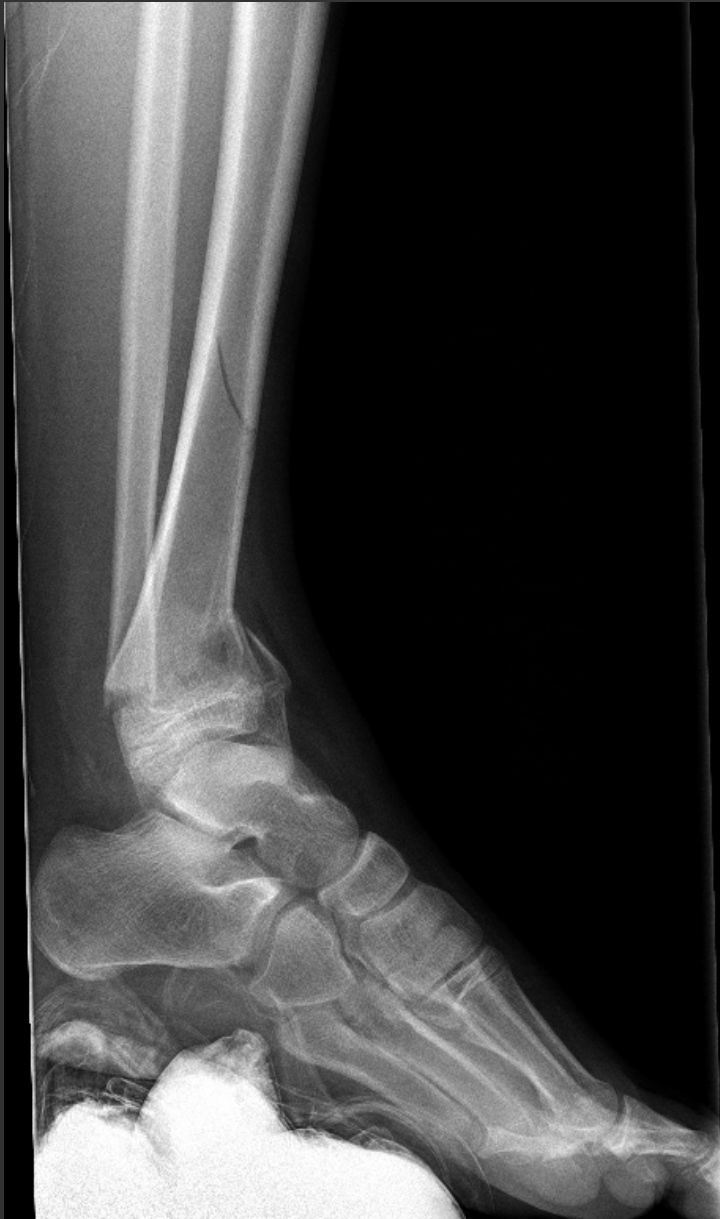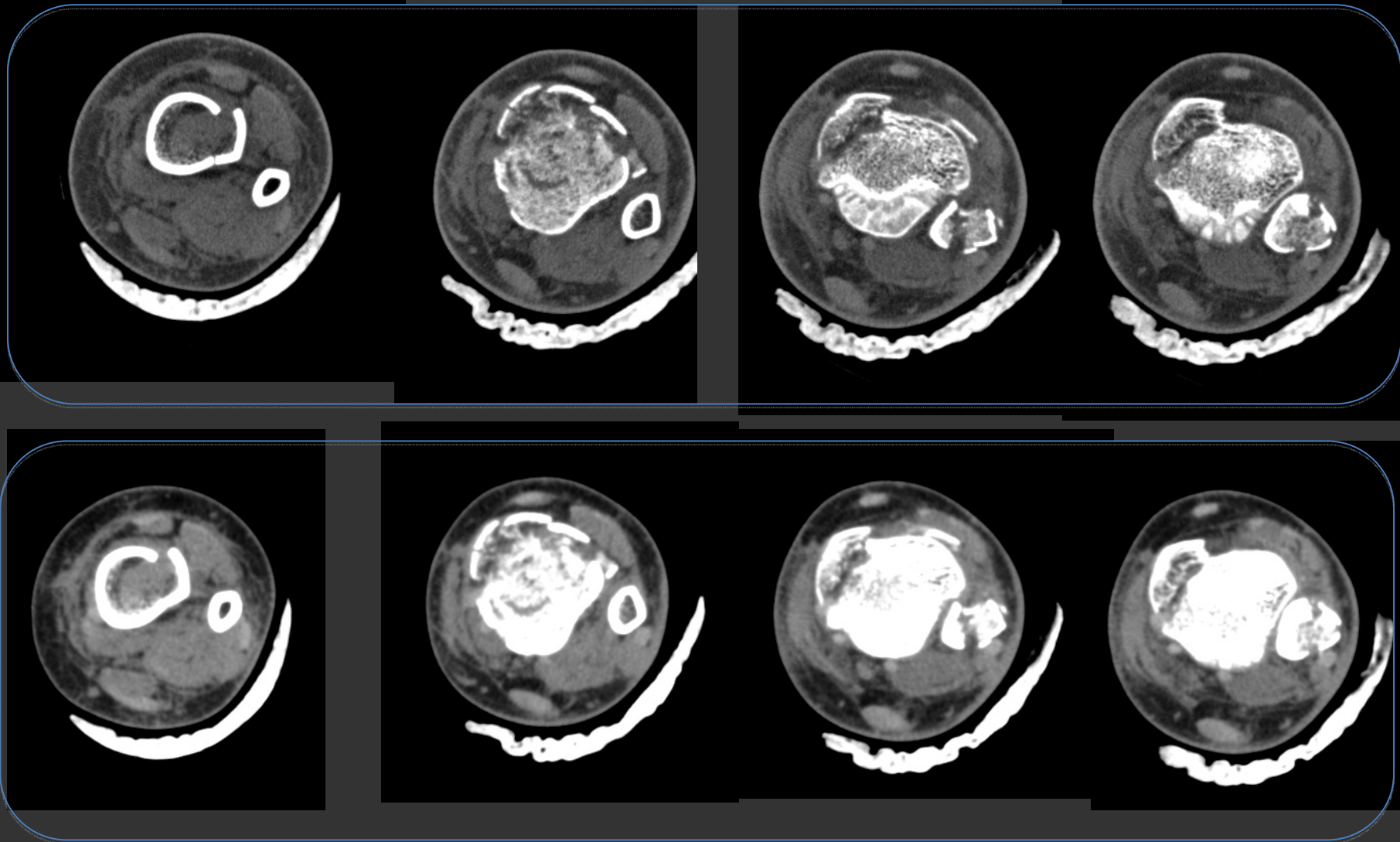


Case 2

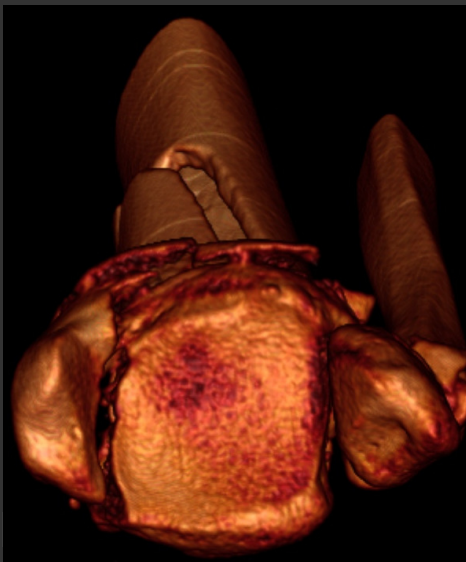
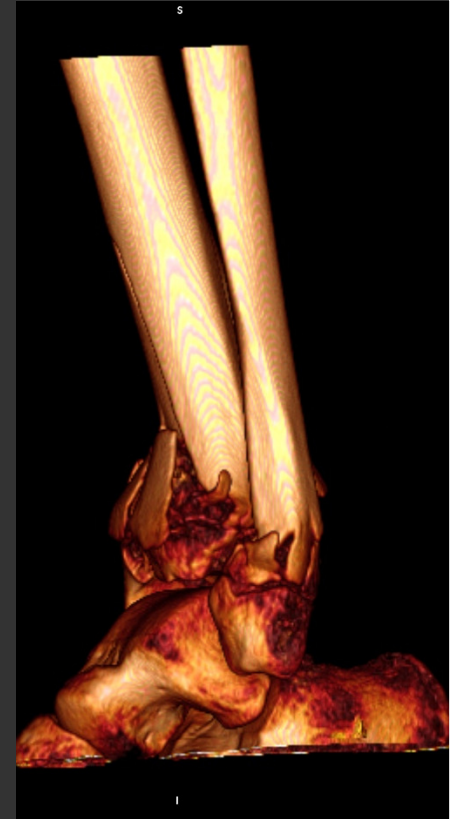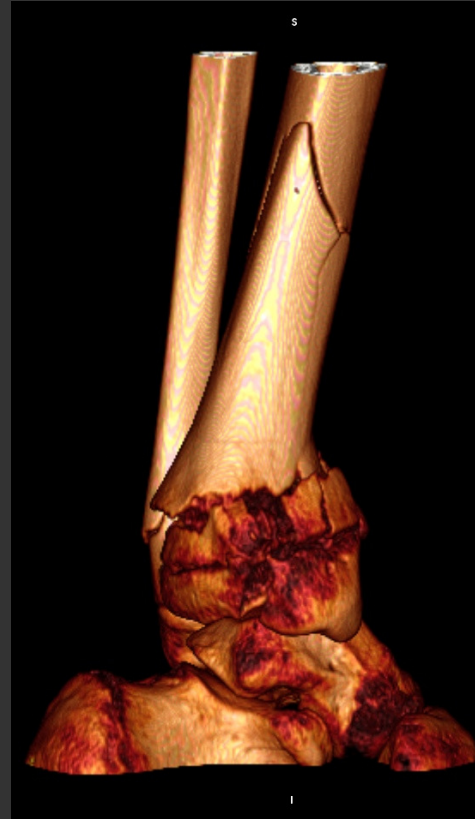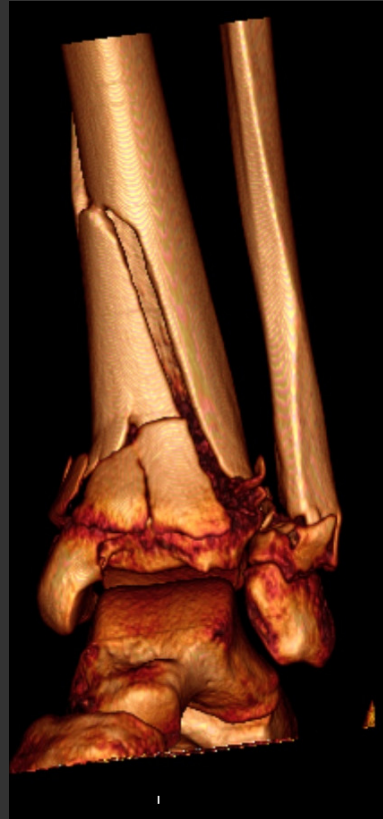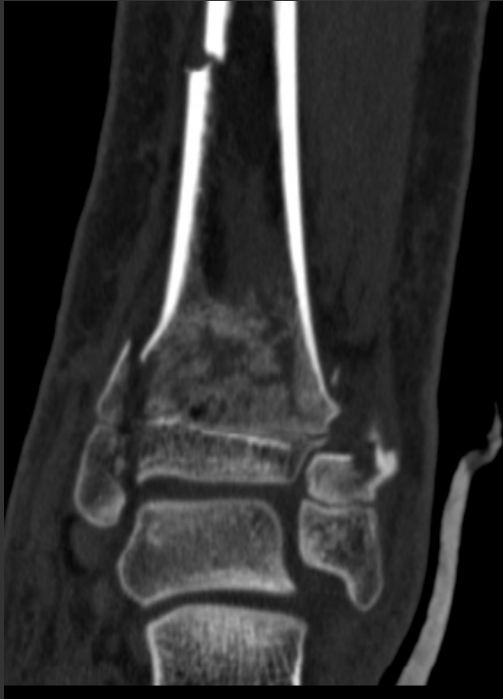- 15 year old boy.
- Trauma to the ankle after fall from height.



AXIAL CT



CORONAL AND VR RECONSTRUCTION



Case 2

SOFT TISSUE VR RECONSTRUCTION

